Modified Pectoral Nerve Block for Unilateral Mastectomy

Samford University
Moffett & Sanders School of Nursing

Jessica Randall, BSN – Dr. Christa Lauren Barnes, DNP, CRNA

Dept. of Nurse Anesthesia, Moffett & Sanders School of Nursing, Samford University

SAMFORD UNIVERSITY

Background

- General anesthesia combined with opioid therapy is the most common anesthetic technique used for patients undergoing breast cancer surgery; however, inhaled anesthetics and opioids are notorious offenders of a fragile immune system and create hemodynamic compromise.
- Regional anesthesia is a safe alternative or adjunct to general anesthesia that effectively reduces perioperative opioid consumption and limits the amount of anesthesia required intraoperatively.[4,6,10]
- The modified pectoral nerve block (Pecs II block) is a regional technique that provides extensive sensory and motor blockade to the nerves supplying the anterior thoracic wall.[1-6]
- This novel approach supersedes conventional regional techniques for procedures involving the breasts and axillary lymph nodes.[2,3]
- Compared to other techniques, the Pecs II block is anatomically less challenging, associated with fewer complications, and has a higher rate of success.[2,3]
- For breast cancer patients undergoing breast surgery, the Pecs II block combined with conscious sedation greatly reduces risks associated with anesthesia and offers long-term benefits.[7-9,13]

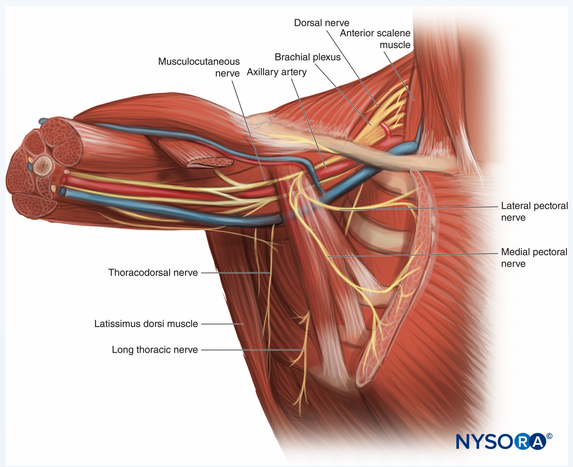

https://www.nysora.com/regional-anesthesia-for-specific-surgical-procedures/thorax/pectoralis-serratus-plane-blocks/

Clinical Question

For breast cancer patients undergoing a mastectomy, is a Pecs II block combined with conscious sedation a safer and more effective technique than general anesthesia combined with opioid administration?

Case Report

- A 93-year-old female presented for a unilateral mastectomy with axillary lymph node dissection related to a malignant tumor in her left breast.
- Pertinent medical history included hypertension, coronary artery disease, congestive heart failure, atrial fibrillation, and a previous 32-pack-year history of smoking.
- The patient was not an ideal candidate for general anesthesia, so a Pecs II block with monitored anesthesia care was determined to be the primary anesthetic plan.
- The patient received the Pecs II block preoperatively.
- Under ultrasound guidance, the four primary landmarks were identified, including the third rib, pectoralis minor and pectoralis major, and the thoracoacromial artery.
- As the tip of the needle approached the first interfascial plane between pectoralis major and minor, a 10 mL injection of 0.25% bupivacaine was administered – this is considered the Pecs I block. To complete the Pecs II block, the needle tip was advanced until it reached the second interfascial plane between the pectoralis minor and the serratus anterior. With the needle tip in the second interfascial plane, a 20 mL injection of 0.25% bupivacaine was administered.
- In the operating room, prior to surgical incision, the patient was administered midazolam 1 mg IV and fentanyl 50 mcg IV, and a propofol infusion was initiated at 40 mcg/kg/min. Within 7 minutes, the patient was consciously sedated as evidenced by an absent response to verbal commands.
- Following surgical incision, evidence of pain was witnessed by the patient's eye-opening and an increase in heart rate. She achieved adequate sedation within 10 minutes as evidenced by an absent response to surgical stimulation and a decrease in respiratory rate following two injections of fentanyl 50 mcg IV, ketamine 12.5 mg IV, and an increase in the propofol infusion rate to 60 mcg/kg/min.
- An infusion containing propofol with ketamine (150 mg and 50 mg, respectively) was initiated at a rate of 0.4 mL/min following completion of the first propofol infusion.
- The patient was administered ketamine 12.5 mg IV following a stimulatory response, her fourth and final rescue dose for analgesia.
- Her total requirements for rescue analgesics included fentanyl 150 mcg IV and ketamine 25 mg IV. She remained adequately sedated and woke up relaxed prior to arriving to PACU.

Level of Evidence

- Senapathi et al. *J Pain Res, 2019* – Melnyk & Fineout-Overholt Level II
- Versyck et al. *J Clin Anesth* , 2017 – Level II
- Blanco et al. *Rev Esp Anestesiol Reanim*, 2012 – Level VI
- Moon et al. *Ann Surg Treat Res*, 2017 – Level VII
- Sato et al. *J Anesth*, 2016 – Level IV
- Wigmore et al. *Anesthesiology*, 2016 – Level IV
- Zhao et al. *Medicine*, 2019 – Level I
- Altiparmak et al. *J Clin Anesth*, 2019 – Level II
- El-Boghdadly et al. *Local Reg Anesth*, 2018 - Level VII
- De Cassai et al. *Korean J Pain*, 2019 – Level IV

Evidence Based Discussion

- Due to the patient's age, cancer diagnosis, and extensive cardiac history, the Pecs II block reduced the risk of hemodynamic instability, immune compromise, and sluggish mental status postoperatively.[7,8]
- Considering the expansive coverage achieved with a Pecs II block, Moon and colleagues suggest that a Pecs II block combined with conscious sedation can replace general anesthesia as the primary anesthetic for patients undergoing breast surgery.[6] A patient undergoing breast surgery received a Pecs II block in combination with conscious sedation and did not require analgesics for 24 hours postoperatively.[6]
- Additionally, evidence supports that a Pecs II block can effectively reduce perioperative opioid requirements.[1,4,6,10,11,13] Senapathi et al found that in patients who received a Pecs II block for a radical mastectomy, intraoperative and 24-hour postoperative opioid consumption were significantly reduced.[1]

Pecs II Block Nerve Coverage

- The Pecs II block anesthetizes eight nerves in the anterior chest wall and axilla:[5,6,10]
- Median and lateral pectoral nerves that supply sensory and motor innervation to the pectoralis minor and major[6,10]
- Thoracodorsal nerve supplying the latissimus dorsi[6,10]
- Long thoracic nerve supplying the serratus anterior[6,10]
- Cutaneous branches of intercostal nerves three through six which supplies sensory innervation to the anterior chest wall[10]
- Intercostal brachial nerve which supplies sensory innervation to the lateral thoracic wall and axilla[10]

Case Critique

- In addition to the Pecs II block, the patient would have benefitted from ketamine being added to the initial propofol infusion for enhanced analgesia in the beginning portion of the case.

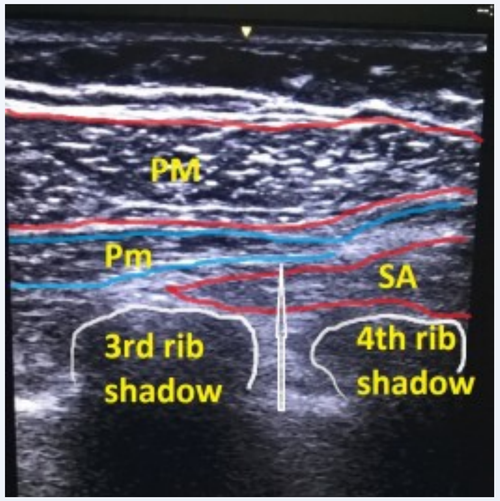

https://www.apicareonline.com/index.php/APIC/article/view/366/1135

Translation to Practice

- Based on what I have synthesized from my research, in future practice I will consider implementing conscious sedation with a Pecs II block for patients undergoing breast cancer surgery.

Translation to Practice

- First, I will present the information to the anesthesia department and provide education based on my research.
- Second, I will formulate a protocol for the implementation of a Pecs II block for patients undergoing a mastectomy secondary to breast cancer and utilize the Iowa Model to implement changes and measure outcomes.

Opioid-Sparing

- Versyck and colleagues found that in patients undergoing a mastectomy and/or sentinel or axillary lymph node dissection, patients who received a Pecs II block were significant for less pain and less required opioid consumption in the post-anesthesia care unit.[4]

Immune System Preservation

- Exadaktylos et al discovered that for patients undergoing general anesthesia for breast cancer surgery, those who received regional anesthesia adjunctively had a 6% rate of recurrence and metastasis within 2.5 years of follow up compared to a 17% rate of recurrence and metastasis for those who received morphine for analgesia.[8]

Future Research

- Being a novel technique used in the field of breast cancer surgery, more evidence is needed to determine the efficacy of using a Pecs II block with conscious sedation as the primary anesthetic for high-risk patients undergoing breast cancer surgery.

References

Scan this QR code for a complete reference list.

Questions?

jhatfiel@Samford.edu